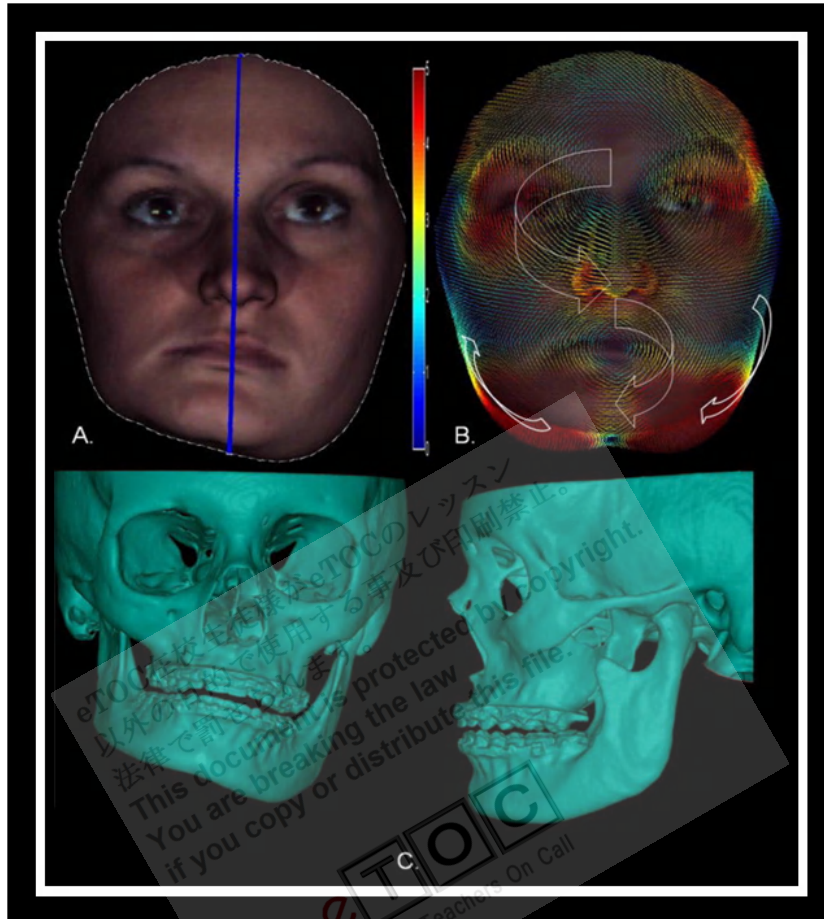


Condylar Hypoplasia



<http://ars.els-cdn.com/content/image/1-s2.0-S0901502712002470-gr2.jpg>

Condylar hypoplasia is facial deformity caused by a short mandibular ramus.

This condition usually results from trauma, infection, or irradiation occurring during the growth period but may be idiopathic. The deformity involves fullness of the face, deviation of the chin to the affected side, an **elongated mandible**, and flatness of the face on the unaffected side. (The side to which the ramus is short causes muscles to appear fuller; the muscles on the unaffected side are stretched so that side appears flatter.) **Mandibular deviation** causes **malocclusion**.

Diagnosis is based on a history of progressive facial asymmetry during the growth period, x-ray evidence of **condylar deformity** and **antegonial notching**

(a depression in the inferior border of the mandible just anterior to the angle of the mandible), and, frequently, a causative history.

Treatment consists of surgical shortening of the unaffected side of the mandible or lengthening of the affected side. **Pre-surgical orthodontic therapy** helps optimize results.

Reference: <http://www.merckmanuals.com>

eTOC在校生徒様がeTOCのレッスン
以外の目的で使用すること及び印刷禁止。
法律で罰せられます。
This document is protected by copyright.
You are breaking the law
if you copy or distribute this file.

eTOC
English Teachers On Call